



Case Report

## COVID-19 infection in pregnant women with preeclampsia and HELLP syndrome, with possible vertical transmission to the fetus: a case report

Sulistiari Retnowati <sup>1</sup>, Alfaina Wahyuni <sup>1✉</sup>, Nabila A Pramono <sup>2</sup>

<sup>1</sup> Department of Obstetrics and Gynecology, Faculty of Medicine, Universitas Muhammadiyah Yogyakarta, Indonesia

<sup>2</sup> Medical Study Program, Faculty of Medicine, Universitas Muhammadiyah Yogyakarta, Indonesia

### ARTICLE INFORMATION

Received: July 01, 2022  
Revised: August 30, 2022  
Accepted: September 06, 2022

### KEYWORDS

Pregnancy; HELLP Syndrome; Preeclampsia; COVID-19

### CORRESPONDENCE

Phone: 081392624544  
E-mail: alfaina.wahyuni@umy.ac.id

### A B S T R A C T

**Background:** During pregnancy, a woman's immune cells undergo cellular and functional alterations, rendering them more vulnerable to illness. Preeclampsia and HELLP syndromes are pregnancy problems and one of Indonesia's leading causes of maternal mortality; COVID-19 infection would exacerbate the situation. The evidence for COVID-19 vertical transmission is not well established, and the report on the incidence of vertical transmission, especially in Indonesia, is still limited.

**Case presentation:** We discuss the case of a 26-year-old, 36 weeks of gestation, with preeclampsia and HELLP syndrome, who was infected with COVID-19 and got severe pneumonia and ARDS. The infant was born by cesarean section, and there was no contact between the infant and mother following delivery. Based on the results of the PCR examination, the baby was also confirmed to have COVID-19 without any symptoms.

**Conclusion:** Vertical transmission during pregnancy is possible in women with a severe type of COVID-19 with preeclampsia and HELLP syndrome.

### INTRODUCTION

Maternal mortality in Indonesia due to COVID-19 infection accounts for 18% of maternal deaths. Until now, research on the relationship between COVID-19 infection during pregnancy and the fetus, especially in Indonesia, is still limited. Pregnant women have a higher risk of contracting viral infections because they belong to a vulnerable group, particularly in women with comorbidities such as preeclampsia and HELLP syndrome compared to the general population.<sup>1-4</sup>

According to a comprehensive review, 7 of 11,580 pregnant women with confirmed COVID-19 died from various reasons, and 16 of 1935 women require Extracorporeal Membrane Oxygenation (ECMO). In a large American study of 406,446 hospitalized maternity women, maternal mortality was considerably more significant for women with COVID-19 (141 deaths per 100,000 women) than for those without COVID-19.<sup>5</sup> Similar to SARS; there is a potential danger of vertical transmission.<sup>6</sup> Additionally, HIV, Ebola, Hepatitis E, and Zika viruses are transmitted verti-

cally by intrauterine transplacental transmission. The INTERCOVID global cohort research from March to October 2020 comprising 18 countries discovered that 54 of 416 neonates delivered to mothers with COVID-19 tested positive.<sup>7</sup>

How and when an infected newborn can influence obstetric management decisions, e.g., best practice delivery options, neonatal care including virus testing procedures, skin-to-skin maternal contact, isolation requirements, and breastfeeding safety. This study documents the presence of COVID-19 infection in pregnant women with preeclampsia and HELLP syndrome who delivered a baby with a COVID-19-positive status. This case report can serve as a learning opportunity for obstetricians, as it demonstrates that some occurrences of COVID-19 infection are accompanied by complex clinical care and can result in maternal fatality.

<https://doi.org/10.30595/medisains.v20i2.14036>

©(2022) by the Medisains Journal. Readers may use this article as long as the work is properly cited, the use is educational and not for profit, and the work is not altered. More information is available at [Attribution-NonCommercial 4.0 International](https://creativecommons.org/licenses/by-nc/4.0/).

## CASE PRESENTATION

A 26-year-old Indonesian woman, G1P0A0, 36 weeks pregnant, came to the Emergency Room at PKU Muhammadiyah Gamping Hospital Yogyakarta, Indonesia, complaining of shortness of breath for three days before being admitted to the hospital and accompanied by diarrhea, painful swallowing, cough, and fever. On physical examination, the patient was conscious, Blood Pressure (BP) 140/94 mmHg, pulse 121 x/minute, Respiration Rate (RR) 38 x/minute, temperature 37.5oC, oxygen saturation (SpO<sub>2</sub>) 88%, with nasal cannula correction for O<sub>2</sub> 5 l/m to 98%. Body weight 85 kg (weight gain 19 kg during pregnancy), Height 154 cm, BMI 35.84. History of regular ANC, with normal BP 120/80 mmHg, the estimated weight of the fetus is 2,540 grams. At 32 weeks of pregnancy, she complained of swollen legs without proteinuria. There was a history of close contact with a husband who worked in Jakarta, with the highest COVID-19 cases in Indonesia then. Laboratory results showed positive SARS-CoV-2 rapid antigen and PCR test. On the X-ray result, besides cardiomegaly, there is a picture of inhomogeneous semiopaque consolidation visible at the periphery of both lungs in an anteroposterior or supine thorax photo (Figure 1A), indicating mild COVID-19 pneumonia.

The patient receives typical COVID-19 treatment from the internal medicine department, consisting of Remdesivir injection of 200 mg/24 hours, Dexamethasone injection of 1 amp/24 hours, Pantoprazole injection of 1 amp/24 hours, Acetylcysteine injection of 200 mg/24 hours, Vitamin C injection 1 amp/24 hours, Vitamin D3 tablets 1x1, Zinc tablets 1x1, Pulmicort 0.25 mg/8 hours. The Obstetrics and Gynecology division discovered a consistent fetal heart rate of 142 beats/minute, BP of 150/89 mmHg, urine protein +3, platelets 142,000 Thousand/uL, SGOT/AST 841 U/L, SGPT/ALT 436 U/L, and albumin level is 2.5 mg/dL. The patient was diagnosed with G1P0A0 at 36 weeks, with suspected COVID-19, severe preeclampsia, and HELLP syndrome. Received additional therapy in the form of Magnesium sulfate injection, fetal lung maturation with dexamethasone injection, and planned for pregnancy termination.

On the second day, the caesarian section was performed. Because the patient had a fever and was experiencing shortness of breath, she was given nebulized Ventolin Pulmicort every 8 hours and a 2 amp injection of Furosemide at the time of caesarian. With regional anesthetic, the caesarian procedure proceeded without a fetal or maternal complication. Baby boy, weight 2,370 grams, heart rate 129x/minute, RR 45x/minute, random glucose 33 mg/dl, not cyanotic, and breathing via nostrils; thus, five times positive pressure ventilation O<sub>2</sub> Continuous Positive Airway Pressure (CPAP)T-Piece and nasal cannula 0.5 L/m were administered. Premature newborns with normal birth

weight asphyxia and hypoglycemia are diagnosed. Babies get prophylactic ampicillin injections of 125 mg and gentamicin 10 mg intravenously and are given donor breast milk. Babies are immediately separated from their mothers at birth.

Following surgery, the mother was admitted to the isolation room due to severe shortness of breath, BP 120/56 mmHg, oxygenated NRM 15 liters/minute, oxygen saturation of 91%, and received additional therapy, including Ceftriaxone injection 2x1gram, tramadol injection 3x1, furosemide injection 1x1, and Infartisone 100 mg/minute. After delivery, the sign of HELLP syndrome improved, as seen in the platelet and liver function test (Table 1), but the sign of infection and respiratory distress worsened.

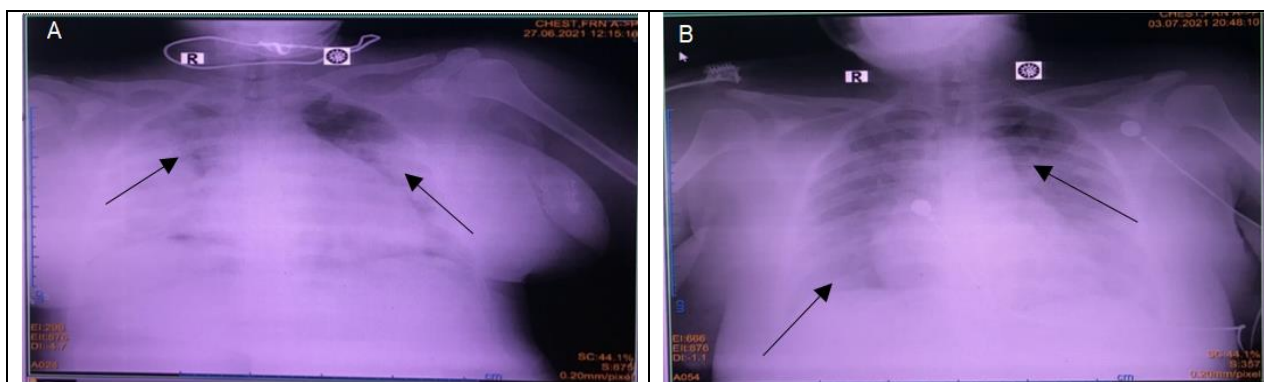
The patient was transported to the Intensive Care Unit (ICU) on the third day following surgery because her shortness of breath had worsened. The examination results were as follows: BP 124/65mmHg, heart rate 81 beats per minute, and SpO<sub>2</sub> 85%. Leukocyte count is 26,800 mm<sup>3</sup>; D Dimer is 19.96 ug/mL; Total protein is 5.3 g/dl; albumin is 2.6 g/dL; CRP is 38.57 mg/L; and lactic acid is 15.57 mg/dL. The patient got NIV FiO<sub>2</sub> 65% CPAP 14 oxygen treatment.

The patient was diagnosed with severe confirmed COVID-19 with secondary infection, sepsis, and hypoalbuminemia. The antibiotic injection was changed to 1x750 mg of Levofloxacin, 100 mg of Fosfomycin every 8 hours, and Albumin correction. The patient's condition deteriorated on the sixth day of therapy. The patient has hematuria and bloody stools. D-dimer examination obtained >20 ug/mL. The results of laboratory examinations from the time the patient entered the hospital until he died are shown in Table 1. The X-ray result after receiving COVID-19 therapy indicates that the inhomogenous semiopaque consolidation in both lungs is still visible (Figure 1B). The patient got NIV PEEP FiO<sub>2</sub> 90% CPAP 14 oxygen treatment, heparin injection 700 lu/hour, and antibiotics were substituted with Meropenem injection 1gr/8 hours. On the ninth day post-therapy, oxygen saturation dropped to 56%. The patient is intubated, and a few hours later, the patient is proclaimed dead.

The findings of the PCR swab screening in the baby revealed that he was infected with the SARS-CoV-2 virus. On the X-ray of the baby's thorax, the chest cavity seemed shaped like a bell, the Bronchovascular in both lungs was expected, and the chest configuration was typical. The infant was stable and active, cried frequently, had an average temperature, and was treated for prophylaxis infection with Ampicillin 2x125 mg and Gentamicin 1x10 mg. The infant got donor breast milk but did not have skin-to-skin contact with his mother since the mother was in the intensive care unit. The infant was discharged on the seventh day of therapy.

**Table 1.** Laboratory Examination

Type	Results								Unit
	1 <sup>st</sup> day	2 <sup>nd</sup> day	3 <sup>rd</sup> day	4 <sup>th</sup> day	5 <sup>th</sup> day	6 <sup>th</sup> day	7 <sup>th</sup> day	8 <sup>th</sup> day	
Antigen	Positive								
PCR SWAB		Positive	Positive						
Hemoglobin	11.8			12.2		11.1			g/dL
Leukocytes	9			19.7		26.5			mm3
Segment Neutrophils	79			84					%
Lymphocytes	14			9					%
Platelets	159	142		197		225			Thousand /uL
Glucose	74								mg/dL
Urea	28		36						mg/dL
Creatinine	1.1		1.2						mg/dL
Albumin				2,5	2,6	2,6			g/dL
Globulins				-2,5	2,7	-2,6			g/dL
Urine Protein		3+							U/L
SGOT/AST		841		340					U/L
SGPT/ALT		436		298					U/L
PPT			12.3		12.8				Second
APTT			47.2		34.8	30.4			Second
D-dimer					19.96	>20			ug/mL
Lactic acid					15.57				mg/dL
CRP					38.57				mg/L
pH			7.31				7.46	7.46	
pCO <sub>2</sub>			30				38	37	mmHg
pO <sub>2</sub>			81				88	45	mmHg
BE			-10.6				2.6	2.2	
TCO <sub>2</sub>			15.5				27.7	27.1	mEq/L
HCO <sub>3</sub>			14.6				26.5	25.9	mEq/L
SO <sub>2</sub>			95				92	80	%

**Figure 1.** Thorax X-ray. 3rd day (A); 9rd day (B). The arrows indicate inhomogeneous semiopaque consolidation

## DISCUSSION

This case study discusses third-trimester pregnant women with COVID-19 and comorbid disorders, including severe preeclampsia and HELLP syndrome. COVID-19 findings are also positive in infants, which is an interesting finding. Does COVID-19 increase the risk of preeclampsia, or does preeclampsia increase the risk of infection with the SARS-CoV-2 virus? Is there vertical transmission from mother to baby? Is the event of vertical transmission related to the severity of COVID-19 disease with comorbid preeclampsia? The description below is related to the case.

COVID-19 is a family of Coronaviridae, which has symptoms ranging from the common cold to severe.<sup>8,9</sup> This virus causes endothelial damage in the lung parenchyma, platelet inflammation, immune dysregulation, and changes in

the Angiotensin-Converting Enzyme 2 (ACE2) pathway.<sup>4,10,11</sup> There is evidence of cytokine storms in COVID-19 infection causing Acute Respiratory Distress Syndrome (ARDS).<sup>12,13</sup> The majority of pregnant women infected with SARS-CoV-2 are asymptomatic. Most symptomatic pregnant women experience only mild or moderate cold or flu-like symptoms.<sup>14</sup> Compared to women who are not pregnant, pregnant women with COVID-19 have a faster rate of disease progression and therefore require higher intensive care unit treatment.<sup>15</sup>

The patient was a primigravida with obesity risk factors (BMI 35.84 kg/m<sup>2</sup>). The patient had previously received antenatal care in a primary health care center, and her pregnancy weight gain was 19 kg. The patient has had leg edema since she was 32 weeks pregnant with negative urine protein findings. So obesity and excessive weight gain are risk factors for preeclampsia in these patients.

The patient presented to the hospital with hypertension, thrombocytopenia, urine protein +3, and an elevation in SGOT/AST and SGPT/ALT. This discovery supports the diagnosis of severe preeclampsia with HELLP syndrome. As soon as severe preeclampsia was diagnosed, the pregnancy was terminated using Magnesium sulfate preparation. The procedure went smoothly under regional anesthetic; however, the mother's BP decreased throughout the process, so the Magnesium sulfate was stopped. In this situation, the mother's health did not improve soon after birth, unlike in most cases of preeclampsia, followed by an improvement in circumstances and laboratory following delivery. This patient's shortness of breath deteriorated after delivery, leading to respiratory failure.

The SARS-CoV-2 virus enters cells through angiotensin-converting enzyme receptor 2 (ACE2), which is overexpressed during normal pregnancy.<sup>10,16</sup> Despite increases in other components of the renin-angiotensin-aldosterone system, increased ACE2 promotes the conversion of angiotensin II (vasoconstrictor) to angiotensin-(1-7) (vasodilator) and results in relatively low BP. Pregnant women may have increased complications of SARS-CoV-2 infection due to increased ACE2 expression. When SARS-CoV-2 binds to ACE2, it downregulates it by reducing angiotensin (1-7) levels which may mimic/reverse the inflammatory and procoagulant effects of vasoconstriction during pregnancy.<sup>17,18</sup>

Pregnant women are at high risk of being infected with COVID-19, especially pregnancies with comorbidities. In women with preeclampsia, endothelial damage, placental oxidative stress, and antiangiogenic status occur, leading to hypertension and proteinuria. This resembles the effect of a COVID-19 infection that attacks the body.<sup>4</sup> Based on the pathophysiology, both in COVID-19 and preeclampsia, there is endothelial damage resulting in hyperinflammation. ACE2 overexpression that occurs in pregnant women with preeclampsia acts on target cells that are also bound by COVID-19. However, Angiotensin 1-7 is at low levels in pregnancy with preeclampsia and COVID-19 infection, so the protective effect in pregnancy is reduced because many ACE2 receptors bind to the COVID-19 virus, which induces vasoconstriction due to dysfunction of the renin-angiotensin system.<sup>17,19</sup>

In this case, the patient suffers from COVID-19, accompanied by severe preeclampsia. Which happened first is still unclear. Preeclampsia has been linked to COVID-19 during pregnancy (RR=1.77).<sup>4</sup> In comparison to moderate COVID-19, severe COVID-19 was substantially linked to preeclampsia (OR=4.16).<sup>19</sup> COVID-19 infections during pregnancy and preeclampsia, according to some authors, have comparable risk factors, such as underlying hypertension, obesity, and diabetes.<sup>15,20,21</sup> Several associations can emerge, such as 1) COVID-19 infection, which can elicit symptoms similar to preeclampsia criteria

(preeclampsia-like syndrome); 2) Physiological alterations have occurred in preeclampsia since early pregnancy; 3) COVID-19 is thought to bring the pathogenesis of preeclampsia.<sup>4,11,22</sup>

Infection with the SARS-CoV-2 virus produces systemic consequences such as high BP, renal problems, thrombocytopenia, and liver damage.<sup>23,24</sup> This occurs because COVID-19 infection alters the expression of ACE2, causing it to manifest as preeclampsia or preeclampsia-like syndrome and inducing a pro-inflammatory state, making the tendency of pregnant women with comorbid preeclampsia much more severe, even if severe respiratory symptoms do not always accompany it. The previous study discovered that COVID-19 infection causes an increase in inflammation in placental mesenchymal stromal cells in preeclampsia pregnancies.<sup>25</sup> Decidual arteriopathy, fibrinoid necrosis, and fetal vascular Malperfusion are the histological changes in images of the placenta from the patient with COVID-19. These changes are not related to inflammatory reactions or hypertension. It is suspected that the placenta is sensitive to the SARS-CoV-2 virus that plays a role in other infectious mechanisms.<sup>26</sup>

This patient suffers from preeclampsia with HELLP Syndrome complications (Hemolysis, High Liver Enzym, and Low Platelet Count). Endothelial damage occurs due to platelet activation in HELLP syndrome, which is also associated with liver infarction and DIC.<sup>27,28</sup> HELLP syndrome is associated with a bad outcome in preeclampsia.<sup>21</sup> SARS-CoV-2 virus infection does liver damage due to preeclampsia becoming aggravated. The liver is the most commonly affected organ besides the respiratory system in patients with severe COVID-19. Patients with severe COVID-19 infection had elevated liver enzymes in approximately 25% of cases.<sup>29</sup> Elevated liver enzymes are a factor implicated in acute liver damage in severe COVID-19 infection, including severe hypoxemia due to respiratory failure, septic shock, and multiorgan dysfunction.<sup>30</sup> This patient had a high increase in SGOT/AST; similar results were obtained in another case study.<sup>30</sup> In addition, there was a similarity in response in the form of a rapid improvement in AST levels after delivery.

An increased incidence of preeclampsia has been reported in mothers infected with SARS-CoV-2 compared to the general population. They differentiated pregnant women with severe COVID-19 preeclampsia from true preeclampsia by measuring sFlt-1/PIGF LDH and trans-abdominal uterine artery doppler pulse index. PIGF and sFlt-1 are placenta-associated angiogenic factors that are highly specific in the pathophysiology of placental insufficiency in preeclampsia. A previous study reported that 8 out of 42 cases of pregnant women with COVID-19 had severe preeclampsia. Five of them had the preeclampsia-like syndrome, while one case showed true preeclampsia.

Two cases of patients with preeclampsia-like syndrome recovered spontaneously after recovering from severe pneumonia.<sup>31</sup>

Shortness of breath in COVID-19 patients with preeclampsia must be careful in determining whether it is caused by pulmonary edema following preeclampsia or pneumonia in COVID-19. In a previous study involving 706 women with COVID-19, 11 maternal deaths (1.6%): 4 cases had severe preeclampsia, 5 cases had worsening respiratory failure antenatally, and 2 cases had fever with shortness of breath within seven days of delivery. Meanwhile, according to metanalysis research, women who were obese during antenatal care and later developed COVID-19 had the highest risk of morbidity and mortality. The same thing happened in the case of this patient. Pregnant patient with COVID-19 preeclampsia and obesity ends in maternal death.<sup>5</sup>

PCR neonate samples taken within 48 hours showed positive results in this case. There is no contact between mother and baby; the baby was born without early breastfeeding initiation and treated in a neonatal isolation room. It is unclear whether neonates' infection resulted from vertical transmission from the mother or contracted after birth. Congenital infection of the neonate can be proven if there is a virus on examination of the amniotic fluid before a membrane tear occurs or is found in the umbilical cord blood or placenta.<sup>32</sup> Transmission of COVID-19 infection occurs through human-to-human respiratory droplets, and another spread of this virus is still a hypothesis, one of which is the transplacental transmission. Based on a case report in Mexico, a baby aged positive for COVID-19 was found through a stool test. Viral RNA was detected in the feces and breast milk of COVID-19-infected mothers who were breastfeeding. This proves that intrauterine infection and breastfeeding are risks as vertical transmission of the COVID-19 virus.<sup>33</sup>

Vertical transmission is the transfer of infectious pathogens from mother to fetus via the placenta or body fluids during pregnancy, contact with the infant at birth, or direct exposure during breastfeeding. There are many reasons for the vertical spread of the COVID-19 virus. SARS-CoV-2 first enters the body through the major receptor ACE2, widely expressed in the placenta and many other female reproductive organs. The ovaries are the uterus and vagina. ACE2 is thus a mediator of embryonic transformation.<sup>17</sup> Vertical transmission is the transfer of infectious pathogens from mother to fetus via the placenta or body fluids during pregnancy, contact with the infant at birth, or direct exposure during breastfeeding. There are many reasons for the vertical spread of the COVID-19 virus. SARS-CoV-2 first enters the body through the major receptor ACE2, widely expressed in the placenta and many other female reproductive organs. The ovaries are the uterus

and vagina. ACE2 is thus a mediator of embryonic transformation.

A previous study found that 12.1% of neonates born to mothers with COVID-19 had positive PCR test results. It is suspected that the contamination originated during the cesarean delivery process.<sup>7</sup> Placental transmission causes vertical transmission in outbreaks of HIV, Ebola, Hepatitis E, and Zika virus but has rarely been seen in previous epidemics of SARS and MERS coronaviruses. ACE2 receptors are abundant in placental tissues during pregnancy, including syncytiotrophoblast, cytotrophoblast, endothelium, and vascular smooth muscle. Pathological examination of the placental anatomy of the fetus with a positive PCR from a mother infected with COVID-19 revealed fetal vascular Malperfusion, and prominent inflammatory infiltrates in the intervillous space. An intense positive signal expression was found for SARS-CoV-2 in the syncytiotrophoblast lining the chorionic villi. Ultrastructural examination revealed coronavirus-like particles in the syncytiotrophoblast's cytoplasm, chorionic villous fibroblasts, and fetal capillary endothelial cells.<sup>34</sup>

Studies conducted by looking at immunoglobulin M (IgM) in newborns with COVID-19 (+) mothers raise suspicions of uteroplacental transmission because IgM cannot enter the placenta, but there is not enough evidence to establish that COVID-19 infection can occur vertically.<sup>34</sup> The possibility of maternal-fetal transmission is still low and rarely occurs during COVID-19 infection. However, some studies have shown that Covid-19 can cause mother-to-child transmission to infants in China due to increased IgM and IgG antibodies and cytokine values in infant blood samples.<sup>9</sup> There are currently no studies on the pathogenesis and appropriate management of mother-to-fetus transmission of COVID-19, but there are reports of a high incidence of COVID-19 infection in infants born to mothers with COVID-19. It is hoped that a large number of reports and data on the discovery of COVID-19 infection in newborns can help encourage further research on its pathogenesis, prevention, and management. In this case, the occurrence of severe preeclampsia and the positive PCR results in the baby support the possibility of a COVID-19 infection mediated through the ACE2 receptor in the placenta.

This case occurred during the peak of the second wave of COVID-19 in Yogyakarta, Indonesia, which resulted in a deficit of health facilities accessible for COVID-19 treatment, a large number of health workers who were confirmed to be COVID-19, and an oxygen crisis owing to excessive oxygen demand. Many limitations in managing this patient include delayed release of maternal PCR results so that treatment is less aggressive—delays caused by PCR examinations being centered in government-appointed laboratories with large queues of samples. The baby was not checked for IgG and IgM Sar Cov 2 levels

because the baby had no symptoms. There is also no examination of cord blood, amniotic fluid, and placenta tissue to confirm the occurrence of vertical transmission in infants.

## CONCLUSIONS AND RECOMMENDATION

Due to changes in their immune systems, pregnant women are more vulnerable to infection. Pregnancy with comorbidities such as preeclampsia and HELLP Syndrome enhances the prevalence of SARS-CoV-2 viral infection and illness development due to an interconnected system, especially the ACE2 receptor. Due to the presence of ACE2 receptors in fetal and placental tissues, this receptor has the potential to transfer the SARS-CoV-2 virus from the mother to the fetus. However, no tests have proved vertical transmission of COVID-19 infection in this case. In the case of pregnant women with COVID-19, management can be more aggressive, especially in cases accompanied by comorbidities such as preeclampsia. Further studies are needed, especially about the possibilities of vertical transmission, so it is hoped that vertical transmission can be prevented.

## REFERENCES

- Hazari KS, Abdeldayem R, Paulose L, et al. Covid-19 infection in pregnant women in Dubai: a case-control study. *BMC Pregnancy Childbirth*. 2021;21(1):658. doi:10.1186/s12884-021-04130-8
- Phoswa WN, Khaliq OP. Is pregnancy a risk factor of COVID-19? *Eur J Obstet Gynecol Reprod Biol*. 2020;252:605-609. doi:10.1016/j.ejogrb.2020.06.058
- Yanti L, Susanti D. Miscarriage in COVID-19 Infection: a case report. *MEDISAINS*. 2021;19(1):23. doi:10.30595/medisains.v19i1.10543
- Papageorghiou AT, Deruelle P, Gunier RB, et al. Preeclampsia and COVID-19: results from the INTERCOVID prospective longitudinal study. *Am J Obstet Gynecol*. Published online June 26, 2021. doi:10.1016/j.ajog.2021.05.014
- Royal College of Obstetricians & Gynaecologist. Coronavirus (COVID-19) Infection in Pregnancy: Information for healthcare professionals Version 14.2. Published online Published online 2021. <https://www.rcog.org.uk/globalassets/documents/guidelines/2021-12-06-coronavirus-covid-19-infection-in-pregnancy-v14.2.pdf>
- Dashraath P, Wong JLJ, Lim MXK, et al. Coronavirus disease 2019 (COVID-19) pandemic and pregnancy. *Am J Obstet Gynecol*. 2020;222(6):521-531. doi:10.1016/j.ajog.2020.03.021
- Villar J, Ariff S, Gunier RB, et al. Maternal and Neonatal Morbidity and Mortality Among Pregnant Women With and Without COVID-19 Infection: The INTERCOVID Multinational Cohort Study. *JAMA Pediatr*. 2021;175(8):817. doi:10.1001/jamapediatrics.2021.1050
- Castro-Vargas RE, Herrera-Sánchez MP, Hernández RR, Rondón-Barragán IS. Antibiotic resistance in *Salmonella* spp. isolated from poultry: A global overview. *Vet World*. 2020;13(10):2070-2084.
- Dhama K, Khan S, Tiwari R, et al. Coronavirus Disease 2019–COVID-19. *Clin Microbiol Rev*. 2020;33(4). doi:10.1128/CMR.00028-20
- Ferrer-Oliveras R, Mendoza M, Capote S, et al. Immunological and physiopathological approach of COVID-19 in pregnancy. *Arch Gynecol Obstet*. 2021;304(1):39-57. doi:10.1007/s00404-021-06061-3
- Jamieson DJ, Rasmussen SA. An update on COVID-19 and pregnancy. *Am J Obstet Gynecol*. Published online September 2021:S0002937821009911. doi:10.1016/j.ajog.2021.08.054
- Joma M, Fovet CM, Seddiqi N, Gressens P, Laforge M. COVID-19 and Pregnancy: Vertical Transmission and Inflammation Impact on Newborns. *Vaccines*. 2021;9(4):391. doi:10.3390/vaccines9040391
- Rosner-Tenerowicz A, Fuchs T, Zimmer-Stelmach A, et al. Placental pathology in a pregnant woman with severe COVID-19 and successful ECMO treatment: a case report. *BMC Pregnancy Childbirth*. 2021;21(1):760. doi:10.1186/s12884-021-04228-z
- Ferraiolo A, Barra F, Kratochwila C, et al. Report of Positive Placental Swabs for SARS-CoV-2 in an Asymptomatic Pregnant Woman with COVID-19. *Medicina (Mex)*. 2020;56(6):306. doi:10.3390/medicina56060306
- Allotey J, Stallings E, Bonet M, et al. Clinical manifestations, risk factors, and maternal and perinatal outcomes of coronavirus disease 2019 in pregnancy: living systematic review and meta-analysis. *BMJ*. Published online September 1, 2020:m3320. doi:10.1136/bmj.m3320
- Mendoza M, Garcia-Ruiz I, Maiz N, et al. Preeclampsia-like syndrome induced by severe COVID-19: a prospective observational study. *BJOG Int J Obstet Gynaecol*. 2020;127(11):1374-1380. doi:10.1111/1471-0528.16339
- Dhaundiyal A, Kumari P, Jawalekar SS, Chauhan G, Kalra S, Navik U. Is highly expressed ACE 2 in pregnant women “a curse” in times of COVID-19 pandemic? *Life Sci*. 2021;264:118676. doi:10.1016/j.lfs.2020.118676
- Narang K, Enninga EAL, Gunaratne MDSK, et al. SARS-CoV-2 Infection and COVID-19 During Pregnancy: A Multidisciplinary Review. *Mayo Clin Proc*. 2020;95(8):1750-1765. doi:10.1016/j.mayocp.2020.05.011
- Wei SQ, Bilodeau-Bertrand M, Liu S, Auger N. The impact of COVID-19 on pregnancy outcomes: a systematic review and meta-analysis. *Can Med Assoc J*. 2021;193(16):E540-E548. doi:10.1503/cmaj.202604
- Amougou SN, Mbita SMM, Danwe D, Tebeu PM. Factor associated with progression to chronic arterial hypertension in women with preeclampsia in Yaoundé, Cameroon. *Pan Afr Med J*. 2019;33. doi:10.11604/pamj.2019.33.200.16857

21. Benfateh M, Cissoko S, Boufettal H, et al. Risk factors and poor prognostic factors of preeclampsia in Ibn Rochd University Hospital of Casablanca: about 401 preeclamptic cases. *Pan Afr Med J.* 2018;31. doi:10.11604/pamj.2018.31.225.14401
22. Di Mascio D, Khalil A, Saccone G, et al. Outcome of coronavirus spectrum infections (SARS, MERS, COVID-19) during pregnancy: a systematic review and meta-analysis. *Am J Obstet Gynecol MFM.* 2020;2(2):100107. doi:10.1016/j.ajogmf.2020.100107
23. Coronado-Arroyo JC, Concepción-Zavaleta MJ, Zavaleta-Gutiérrez FE, Concepción-Urteaga LA. Is COVID-19 a risk factor for severe preeclampsia? Hospital experience in a developing country. *Eur J Obstet Gynecol Reprod Biol.* 2021;256:502-503. doi:10.1016/j.ejogrb.2020.09.020
24. Donders, F., Lonnée-Hoffmann, R., Tsiakalos, A., Mendling, W., et al. ISIDOG Recommendations Concerning COVID-19 and Pregnancy. *Diagnostics.* 2020;10(4):243. doi:https://doi.org/10.3390/diagnostics10040243
25. Todros T, Masturzo B, De Francia S. COVID-19 infection: ACE2, pregnancy and preeclampsia. *Eur J Obstet Gynecol Reprod Biol.* 2020;253:330. doi:10.1016/j.ejogrb.2020.08.007
26. Hashem NM, Abdelnour SA, Alhimaidi AR, Swelum AA. Potential impacts of COVID-19 on reproductive health: Scientific findings and social dimension. *Saudi J Biol Sci.* 2021;28(3):1702-1712. doi:10.1016/j.sjbs.2020.12.012
27. El Allani L, Benlankaddem S, Berdai MA, Harandou M. A case of massive hepatic infarction in severe preeclampsia as part of the HELLP syndrome. *Pan Afr Med J.* 2020;36. doi:10.11604/pamj.2020.36.78.23302
28. Futterman I, Toaff M, Navi L, Clare CA. COVID-19 and HELLP: Overlapping Clinical Pictures in Two Gravid Patients. *Am J Perinatol Rep.* 2020;10(02):e179-e182. doi:10.1055/s-0040-1712978
29. Wijarnpreecha K, Ungprasert P, Panjawatanan P, et al. COVID-19 and liver injury: a meta-analysis. *Eur J Gastroenterol Hepatol.* 2021;33(7):990-995. doi:10.1097/MEG.0000000000001817
30. Ronnje L, Länsberg JK, Vikhareva O, Hansson SR, Herbst A, Zaigham M. Complicated COVID-19 in pregnancy: a case report with severe liver and coagulation dysfunction promptly improved by delivery. *BMC Pregnancy Childbirth.* 2020;20(1):511. doi:10.1186/s12884-020-03172-8
31. Shah PS, Diambomba Y, Acharya G, Morris SK, Bitnun A. Classification system and case definition for SARS-CoV-2 infection in pregnant women, fetuses, and neonates. *Acta Obstet Gynecol Scand.* 2020;99(5):565-568. doi:10.1111/aogs.13870
32. Hinojosa-Velasco A, de Oca PVBM, García-Sosa LE, et al. A case report of newborn infant with severe COVID-19 in Mexico: Detection of SARS-CoV-2 in human breast milk and stool. *Int J Infect Dis.* 2020;100:21-24. doi:10.1016/j.ijid.2020.08.055
33. Schwartz DA, Thomas KM. Characterizing COVID-19 maternal-fetal transmission and placental infection using comprehensive molecular pathology. *EBioMedicine.* 2020;60:102983. doi:10.1016/j.ebiom.2020.102983
34. Kotlyar AM, Grechukhina O, Chen A, et al. Vertical transmission of coronavirus disease 2019: a systematic review and meta-analysis. *Am J Obstet Gynecol.* 2021;224(1):35-53.e3. doi:10.1016/j.ajog.2020.07.049