



Case Report

# Rupture of the internal jugular vein and tension pneumothorax in a penetrating neck-lung injury due to iron splinters: a case report

Brilliant <sup>1,3</sup>, Muhammad Sabri <sup>1✉</sup>, Annisa Tria Fadilla <sup>2</sup>, Hariadi Hatta <sup>1,3</sup>

<sup>1</sup> Division of Cardiothoracic Vascular Surgery, Arifin Achmad Hospital, Pekanbaru, Riau, Indonesia

<sup>2</sup> Division of Cardiovascular Medicine, Arifin Achmad Hospital, Pekanbaru, Riau, Indonesia

<sup>3</sup> Department of Cardiothoracic Vascular Surgery, Faculty of Medicine, Universitas Riau, Pekanbaru, Riau, Indonesia

## ARTICLE INFORMATION

Received: November 07, 2023

Revised: December 23, 2023

Accepted: August 18, 2024

## KEYWORDS

Lung Injury; Pneumothorax; Neck Injuries

## CORRESPONDENCE

Phone: 082255744573

E-mail: sabriaby03@gmail.com

## ABSTRACT

**Background:** Penetrating neck injuries are relatively rare but pose significant challenges due to the concentration of vital structures in this area. This case report presents a unique in-stance of a 20-year-old male with a penetrating neck injury caused by iron splinters, resulting in the rupture of the internal jugular vein and tension pneumothorax.

**Case Presentation:** The patient, a 20-year-old male, presented with restlessness, chest pain, rapid breathing, and a penetrating wound on the left side of the neck. Initial management included needle decompression for tension pneumothorax and radiological assessments to localize the foreign body. C-arm revealed that the foreign body had penetrated the upper left thoracic region and lung parenchyma. The surgical intervention involved repairing the internal jugular vein and performing pulmonary resection to remove the iron splinters.

**Conclusions:** This case highlights the importance of a multidisciplinary approach in managing complex penetrating neck injuries. Advanced imaging techniques and timely surgical interventions are crucial for optimizing patient outcomes. Future research should focus on refining diagnostic protocols and exploring minimally invasive surgical techniques to improve the management of such injuries.

## INTRODUCTION

Penetrating neck injuries are relatively rare but pose significant challenges due to the concentration of vital structures in this area. Such injuries account for approximately 5-10% of all trauma cases presenting to emergency departments and are associated with significant morbidity and mortality.<sup>1</sup> Management of these injuries requires a thorough understanding of the neck anatomy and a systematic approach to diagnosis and treatment. The neck is divided into three zones to help guide clinical decisions: Zone I extends from the clavicle to the cricoid cartilage, Zone II from the cricoid cartilage to the angle of the mandible, and Zone III from the angle of the mandible to the base of the skull.<sup>2</sup>

Penetrating injuries to Zone I are particularly challenging due to the presence of critical structures such as the subclavian vessels, trachea, esophagus, and the apex of the lungs. While there are reports in the literature on the

management of penetrating neck injuries, the specific combination of internal jugular vein rupture and tension pneumothorax caused by iron splinters is not well-documented.<sup>3</sup> Previous reports have primarily focused on isolated injuries and do not comprehensively address the complexities involved when multiple critical structures are injured simultaneously.

This case report presents a 20-year-old male with a penetrating neck injury caused by iron splinters, resulting in rupture of the internal jugular vein and tension pneumothorax. The unique aspects of this case, including the mechanism of injury and the management challenges, highlight significant gaps in the current literature. This report aims to provide a detailed analysis of the clinical presentation, diagnostic process, and management strategies employed in this case, thereby contributing to a better understanding of such complex injuries and enhancing clinical practice for similar future cases.

<https://doi.org/10.30595/medisains.v22i2.19725>

©(2024) by the Medisains Journal. Readers may use this article as long as the work is properly cited, the use is educational and not for profit, and the work is not altered. More information is available at [Attribution-NonCommercial 4.0 International](https://creativecommons.org/licenses/by-nc/4.0/).

## CASE REPORT

A 20-year-old male patient presented to the emergency department with neck bleeding (Figure 1). After history taking, a foreign body in the form of iron splinters that bounced into his neck accidentally while sitting in the workshop was suspected. On initial examination, the patient presented with restlessness, chest pain, rapid breathing, and a penetrating wound on the left side that injured the blood vessels in the neck zone 1. BP 100/70, HR 80 x/min, RR 30 x/min, SpO2 95%, then initial treatment was carried out, namely 100% oxygen with ambu bag and overcoming the stretching with pressure weights. Thoracic examination showed asymmetrical chest movement, and no bruises or open wounds were found. Breath sounds decreased when auscultated in the left chest.

From the symptoms and physical examination, tension pneumothorax was suspected, then needle decompression was performed. A radiological examination was performed to see the affected neck structure, but it was difficult to assess because the foreign body was not found in the neck (Figure 2a); when further observation was detected that the foreign body was in the upper left thoracic projection, then a thoracic X-ray examination was performed to further confirm the position of the foreign body, with the results found that the foreign body had penetrated the lung parenchyma in the upper left projection (Figure 2b).

After obtaining consent from the family, the patient was immediately taken to the operating room for internal jugular vein repair with surgical exploration and to evacuate the corpus alienum thoracotomy with the help of a C-arm (Figure 3a), it was decided to perform pulmonary resection (Figure 3b) to remove the remnants of iron debris in the surrounding lung tissue, from the results of pulmonary resection obtained 2x2 cm foreign body (Figure 3c). Then, before the patient was discharged from the hospital, an X-ray examination was carried out again, and the results were that the X-rays were within normal limits (Figure 4).

## DISCUSSION

Penetrating neck injuries (PNIs) pose significant diagnostic and therapeutic challenges due to the dense concentration of vital structures in the neck region. These injuries account for a notable percentage of trauma cases and require prompt and precise management to prevent severe complications.<sup>1-3</sup>

### *Clinical Presentation and Initial Management*

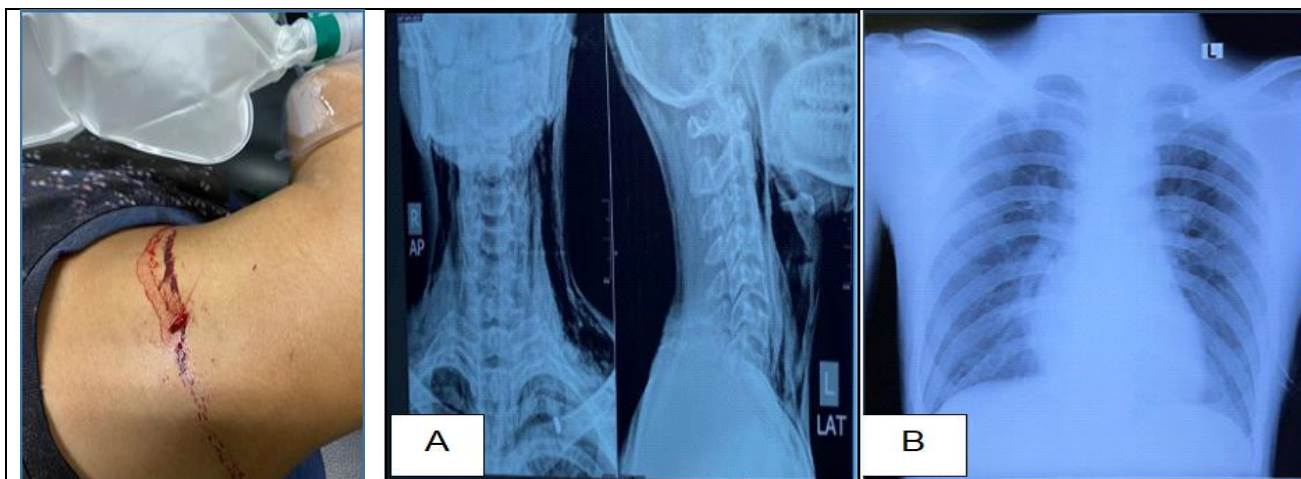
The patient presented with restlessness, chest pain, rapid breathing, and a penetrating wound on the left side of the neck. These symptoms, along with decreased breath sounds in the left chest, indicated tension pneumothorax, a life-threatening condition requiring immediate intervention. Tension pneumothorax is characterized by the accumulation of air in the pleural space, leading to increased intrathoracic pressure, which can cause respiratory and cardiovascular collapse if not promptly treated. Initial management involved needle decompression, critical for relieving intrathoracic pressure and restoring cardiopulmonary function. Needle decompression is the first-line treatment for tension pneumothorax and involves inserting a needle into the pleural space to allow trapped air to escape, thereby reducing pressure on the lungs and heart.<sup>4</sup>

### *Diagnostic Challenges and Imaging*

The initial difficulty localizing the foreign body highlights a common issue in managing PNIs. Penetrating neck injuries often present complex diagnostic challenges due to the intricate anatomy of the neck, which contains numerous vital structures within a confined space. Accurate localization of foreign bodies is crucial for effective treatment but can be difficult due to overlapping tissues and potential object migration within the body.

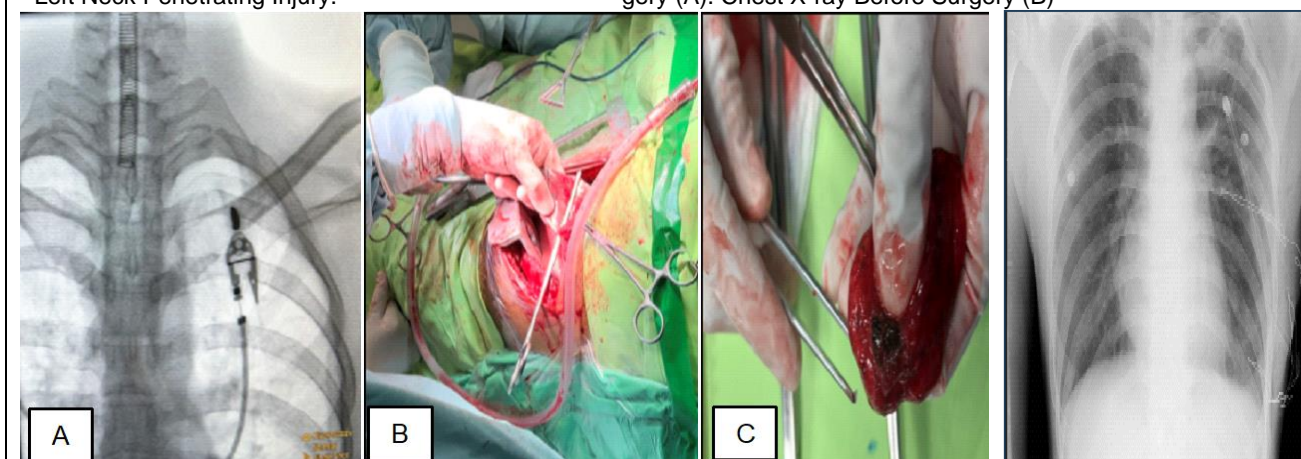
Advanced imaging techniques, particularly computed tomography (CT) angiography, have significantly enhanced the ability to diagnose and plan the treatment of PNIs by providing detailed images of vascular and aerodigestive structures. CT angiography offers superior visualization of soft tissues, blood vessels, and penetrating objects' trajectories compared to conventional radiography. This imaging modality allows for a more precise assessment of injury extent and helps in identifying associated complications, such as vascular damage and airway involvement.<sup>3,5,6</sup>

Despite these advancements, precise localization can still be challenging, necessitating a combination of imaging techniques and clinical correlation. Factors such as the size and composition of the foreign body, patient movement, and the presence of other injuries can affect imaging accuracy. In some cases, additional imaging modalities, including magnetic resonance imaging (MRI) or ultrasound, may be employed to complement CT findings and provide a more comprehensive evaluation. Clinicians must also integrate imaging results with clinical examination and patient history to ensure accurate diagnosis and optimal treatment planning.



**Figure 1.** Clinical Photo of the Left Neck Penetrating Injury.

**Figure 2.** The X-ray Examination of the Neck in AP View and lateral View Before Surgery (A). Chest X-ray Before Surgery (B)



**Figure 3.** Clinical Photo of the Preoperative C-arm Check. (A) Removal of Corpus Ailienum by Wedge Resection. (B) Iron Flakes in the Lung after Wedge Resection (C)

**Figure 4.** Chest X-ray After Surgery

### **Surgical Intervention**

The decision to proceed with surgical exploration was based on the patient's clinical instability and radiological findings. The surgical intervention involved repairing the internal jugular vein and performing pulmonary resection to remove iron splinters from the lung parenchyma. This case demonstrates the importance of a multidisciplinary approach, involving trauma surgeons, thoracic surgeons, and radiologists for successful outcomes. Recent literature supports the selective approach to neck exploration, guided by imaging findings and clinical symptoms, to reduce unnecessary surgical interventions and associated complications.<sup>6,7</sup>

### **Postoperative Care and Outcomes**

The patient had an uneventful postoperative recovery, and follow-up imaging confirmed the resolution of the pneumothorax and the absence of residual foreign bodies. This outcome underscores the effectiveness of comprehensive initial management and timely surgical intervention in

managing PNIs with thoracic complications. Studies indicate that early and accurate diagnosis, combined with prompt surgical intervention, significantly improves patient outcomes in cases of penetrating neck injuries with associated thoracic complications. Advanced imaging techniques, such as CT angiography, are crucial in initial diagnosis and postoperative follow-up to ensure the complete resolution of injuries.<sup>3,5,6</sup>

Effective management strategies, including the use of advanced imaging modalities and timely surgical interventions, have been associated with positive outcomes and reduced complication rates in patients with penetrating neck injuries. The previous study demonstrated that selective non-operative management, guided by clinical assessment and imaging findings, led to successful outcomes in a significant proportion of patients without the need for surgical exploration. Furthermore, follow-up care involving detailed imaging assessments ensures that complications such as residual foreign bodies or unresolved pneumothorax are promptly identified and managed, contributing to favorable long-term outcomes.<sup>7-9</sup> In summary, the integration of advanced diagnostic imaging, effective

initial management, and meticulous postoperative care is essential for optimizing patient outcomes in penetrating neck injuries with associated thoracic complications.<sup>10</sup>

## CONCLUSIONS AND RECOMMENDATION

This case report contributes to the existing body of knowledge by documenting a rare combination of injuries and their successful management. It highlights the critical importance of a rapid, coordinated approach in diagnosing and treating penetrating neck injuries involving multiple critical structures. Advanced imaging techniques, timely surgical interventions, and coordinated care among specialists are essential for optimizing patient outcomes. Future research should focus on refining diagnostic protocols and exploring minimally invasive surgical techniques to improve the management of such complex injuries.

## REFERENCES

- Varghese A. Penetrating neck injury: a case report and review of management. *Indian J Surg.* 2013;75(1):43-46. doi:10.1007/s12262-012-0531-7
- Forner D, Noel CW, Guttman MP, et al. Blunt Versus Penetrating Neck Trauma: A Retrospective Cohort Study. *Laryngoscope.* 2021;131(4):E1109-E1116. doi:10.1002/lary.29088
- Burgess CA, Dale OT, Almeyda R, Corbridge RJ. An evidence based review of the assessment and management of penetrating neck trauma. *Clin Otolaryngol.* 2012;37(1):44-52. doi:10.1111/j.1749-4486.2011.02422.x
- Martin M, Satterly S, Inaba K, Blair K. Does needle thoracostomy provide adequate and effective decompression of tension pneumothorax?. *J Trauma Acute Care Surg.* 2012;73(6):1412-1417. doi:10.1097/TA.0b013e31825ac511
- Chandrananth ML, Zhang A, Voutier CR, et al. 'No zone' approach to the management of stable penetrating neck injuries: a systematic review. *ANZ J Surg.* 2021;91(6):1083-1090. doi:10.1111/ans.16600
- Múnera F, Soto JA, Palacio DM, et al. Penetrating neck injuries: helical CT angiography for initial evaluation. *Radiology.* 2002;224(2):366-372. doi:10.1148/radiol.2242010973
- Borsetto D, Fussey J, Mavuti J, Colley S, Pracy P. Penetrating neck trauma: radiological predictors of vascular injury. *Eur Arch Otorhinolaryngol.* 2019;276(9):2541-2547. doi:10.1007/s00405-019-05517-2
- Tallon JM, Ahmed JM, Sealy B. Airway management in penetrating neck trauma at a Canadian tertiary trauma centre [published correction appears in CJEM. 2007 May;9(3):181. *CJEM.* 2007;9(2):101-104. doi:10.1017/s148180350001486x
- George E, Khandelwal A, Potter C, et al. Blunt traumatic vascular injuries of the head and neck in the ED. *Emerg Radiol.* 2019;26(1):75-85. doi:10.1007/s10140-018-1630-y
- Teixeira F, Menegozzo CA, Netto SD, et al. Safety in selective surgical exploration in penetrating neck trauma. *World J Emerg Surg.* 2016;11:32. doi:10.1186/s13017-016-0091-4