



Original Article

## Effectiveness of wamena pugima honey on incision wound healing: an experimental study

Kismiyati <sup>1✉</sup>, La Jumu <sup>1</sup>, Zeth Robeth Felle <sup>1</sup>

<sup>1</sup> Department of Nursing, Poltekkes Kemenkes Jayapura, Jayapura, Indonesia

### ARTICLE INFORMATION

Received: Januari 05, 2026

Revised: March 30, 2026

Accepted: April 20, 2026

### KEYWORDS

Honey; Wound Healing; Anti-Inflammatory Agents; Anti-Bacterial Agents; Phytochemicals

### CORRESPONDENCE

Phone: 082238227273

E-mail: kismingroho@gmail.com

### ABSTRACT

**Background:** Honey contains bioactive compounds that may accelerate wound healing; however, its therapeutic effectiveness varies depending on botanical origin. Wamena Pugima honey, a local Papuan honey, is presumed to possess unique bioactive properties due to endemic flora, yet its efficacy in wound healing has not been scientifically evaluated.

**Objective:** This study aimed to evaluate the effectiveness of Pugima honey on incision wound healing using a Swiss Webster mouse model.

**Methods:** This experimental study employed a randomized controlled design involving 36 male Swiss Webster mice, randomly allocated into three groups (n = 12 per group): positive control 1 (C1, 3% oxytetracycline ointment), combination control (C2, oxytetracycline ointment plus Pugima honey), and treatment group (P1, Pugima honey). Phytochemical screening was conducted to identify bioactive compounds. Wound length was measured on Days 3, 7, 9, 13, and 14, and wound contraction percentage was calculated accordingly. Statistical analysis was performed using the Kruskal–Wallis test followed by Dunn's post hoc test.

**Results:** Phytochemical screening revealed the presence of flavonoids, phenols, tannins, and saponins, indicating potential anti-inflammatory and antibacterial properties. The Pugima honey group (P1) demonstrated significantly accelerated wound healing compared to both control groups, with shorter wound length observed as early as Day 3 (10.50 ± 1.83 mm vs. 14.00 ± 1.12 mm in C1; p = 0.001).

**Conclusions:** Pugima honey significantly enhances incision wound healing, particularly during the early to intermediate phases, and shows potential as a natural therapeutic agent for wound management.

## INTRODUCTION

Wound healing is a complex biological process involving the coordinated interactions of cells, growth factors, and inflammatory mediators to restore tissue integrity.<sup>1</sup> Inadequately managed wounds may progress into chronic or infected conditions, leading to delayed healing and increased risk of complications. Acute wounds, such as incision wounds, are commonly used as experimental models because their healing processes are predictable and measurable.<sup>2</sup>

Honey has long been used as a natural remedy for wound care. Contemporary evidence demonstrates that honey possesses antibacterial, anti-inflammatory, and antioxidant properties that contribute to tissue regeneration and infection control.<sup>3-5</sup> Among various types, Manuka honey has been extensively studied and shown to accelerate

wound healing and prevent infection.<sup>6</sup> Additionally, the combination of honey with bioactive compounds such as curcumin has demonstrated enhanced healing outcomes and reduced pain in clinical settings, including episiotomy wounds.<sup>7</sup>

The therapeutic properties of honey vary depending on its botanical origin and chemical composition. Previous studies have reported that local honey varieties exhibit distinct antibacterial and antioxidant activities influenced by nectar sources and environmental conditions.<sup>8,9</sup> For instance, Japanese honey has shown strong antibacterial effects, while Sumbawa forest honey from Indonesia has demonstrated efficacy in accelerating incision wound healing in experimental animal models and inhibiting *Staphylococcus aureus*.<sup>10</sup> Despite these findings, scientific evidence on many local honey types remains limited.

<https://doi.org/10.30595/medisains.v24i1.30299>

©(2026) by the Medisains Journal. Readers may use this article as long as the work is properly cited, the use is educational and not for profit, and the work is not altered. More information is available at [Attribution-NonCommercial 4.0 International](https://creativecommons.org/licenses/by-nc/4.0/).

Pugima honey, a local Papuan honey produced by *Apis mellifera* utilizing endemic highland flora, represents a potentially valuable but underexplored natural resource. The unique environmental conditions of Wamena, including low temperatures, high humidity, and distinct vegetation, may influence the bioactive composition of this honey. Preliminary evidence suggests that Pugima honey contains flavonoids, phenols, and saponins, which are associated with anti-inflammatory and antibacterial activities, indicating its potential role in wound healing.

However, despite its traditional use, no experimental study has specifically evaluated the effectiveness of Pugima honey in a controlled incision wound model. Therefore, this study aimed to evaluate the effectiveness of Pugima honey in accelerating incision wound healing using a Swiss Webster mouse model.

## METHOD

### Study Design

This study employed a randomized controlled experimental design.<sup>11</sup>

### Study Site

The study was conducted over a 14-day period at the Animal Research Laboratory of the Papua Public Health Laboratory, Papua, Indonesia.

### In Vivo Procedure

#### Animal Preparation

A total of 36 male Swiss Webster mice, aged 8 weeks and weighing 20–30 g, were used in this study. The animals were housed individually under controlled conditions (22–25°C, 12-hour light–dark cycle) and acclimatized for 7 days prior to experimentation. Inclusion criteria included healthy mice within the specified weight range. Exclusion criteria comprised mice showing signs of illness (e.g., weight loss, lethargy), those outside the weight range, and those that did not respond adequately to anesthesia.

#### Experimental Procedure

Block randomization was used to allocate the mice (N = 36) into three groups (n = 12 per group): Positive control 1 (C1): 3% oxytetracycline ointment; Positive control 2 (C2): combination of oxytetracycline ointment and Pugima honey; Treatment group (P1): Pugima honey.

#### Incision of Incision Wound

An incision was created on the dorsal region of each mouse. Prior to the procedure, mice were anesthetized with ketamine (80 mg/kg body weight) and xylazine (2.5 mg/kg body weight) administered intraperitoneally. Adequate anesthesia was confirmed by the absence of response to pain stimuli. The dorsal area was shaved and disinfected with 70% alcohol and povidone-iodine. A standardized incision measuring 15 mm in length and 3 mm in depth was made using a sterile scalpel.

### Wound Treatment

Following incision, treatments were administered twice daily at 12-hour intervals: P1: 0.1 mL Pugima honey applied topically; C1: 3% oxytetracycline ointment; C2: combination therapy of Pugima honey and oxytetracycline ointment (dose requires clarification).

### Wound Monitoring

Wounds were assessed twice daily to monitor healing and detect signs of infection or inflammation. General animal conditions, including appetite and activity, were also monitored. Mice showing severe infection or distress were excluded from the study. Food and water were provided ad libitum.

### Outcome Measurement

Wound length was measured on Days 3, 7, 9, 13, and 14 using a sterile wound measuring guide (Sammons Preston). Wound contraction was calculated as the percentage reduction in wound length relative to baseline measurements.

### Statistical Analysis

Data were analyzed using the Kruskal–Wallis test followed by Dunn's post hoc test for pairwise comparisons. A p-value < 0.05 was considered statistically significant.

### Ethical Consideration

This study was approved by the Animal Ethics Committee of the Faculty of Veterinary Medicine, Universitas Gadjah Mada (No. 119/EC-FKH/int./2024).

## RESULTS

### Phytochemical Screening Results of Pugima Honey

Phytochemical screening revealed that Pugima honey contains flavonoids, phenols, tannins, and saponins. The honey also demonstrated antibacterial activity against *Escherichia coli*, *Propionibacterium acnes*, and *Staphylococcus aureus* (Table 1).

**Table 1.** Antibacterial Activity of Pugima Honey

Bacteria	Repl cate I (mm)	Repl cate II (mm)	Repl cate III (mm)	Me an (m m)	Acti ty Cate gory
<i>Staphylo ccus aureus</i>	10.70	9.23	9.89	9.8 9	Mediu m
<i>Escherichia coli</i>	13.30	10.40	11.31	11. 31	Stron g
<i>Propionibac terium acnes</i>	11.40	11.14	11.27	11. 27	Stron g

Note: Values represent inhibition zone diameters.

### Effect of Pugima Honey on Wound Length

The Pugima honey group (P1) exhibited significantly shorter wound length compared to both control groups (C1

and C2) at all observation points, except on Day 14 (Table 2). Post hoc analysis confirmed significant differences between P1 and both control groups from Day 3 to Day 13 (Table 3).

### Effect of Pugima Honey on Wound Contraction

The Pugima honey group (P1) showed a significantly higher rate of wound contraction compared to both control groups at all observation points, except on Day 14 (Table 4). Pairwise comparisons indicated consistent significant differences between P1 and the control groups across observation periods (Table 5).

**Table 2.** Effect of Pugima Honey on Wound Length

Day	C2 (mm)	C1 (mm)	P1 (mm)	p-value
Day 3	14.08 ± 1.24	14.00 ± 1.12	10.50 ± 1.83	<0.001
Day 7	9.25 ± 2.05	7.00 ± 2.69	4.25 ± 2.00	<0.001
Day 9	8.33 ± 1.96	6.41 ± 2.31	2.91 ± 1.16	<0.001
Day 13	3.41 ± 1.97	3.66 ± 1.96	0.25 ± 0.45	<0.001
Day 14	0.58 ± 1.50	0.08 ± 0.28	0.00 ± 0.00	0.326

Note: C1 = positive control (3% oxytetracycline ointment); C2 = combination therapy; P1 = Pugima honey.

**Table 3.** Pairwise Comparison of Wound Length

Day	Comparison	Mean Difference (mm)	p-value
Day 3	P1 – C1	3.50	0.001
	P1 – C2	3.58	<0.001
	C1 – C2	0.08	1.000
Day 7	P1 – C1	2.75	0.028
	P1 – C2	5.00	<0.001
	C1 – C2	2.25	0.327
Day 9	P1 – C1	3.50	0.006
	P1 – C2	5.41	<0.001
	C1 – C2	1.91	0.350
Day 13	P1 – C1	3.41	<0.001
	P1 – C2	3.16	<0.001
	C1 – C2	0.25	1.000

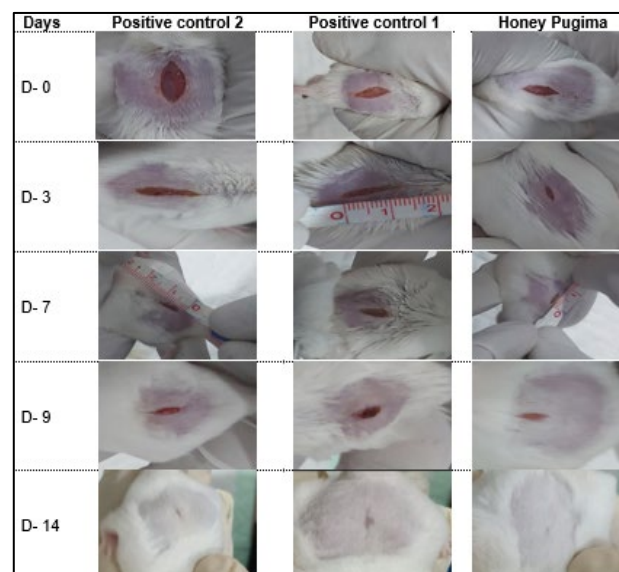
**Table 4.** Effect of Pugima Honey on Wound Contraction

Day	C2 (%)	C1 (%)	P1 (%)	p-value
Day 3	6.11 ± 8.26	6.66 ± 7.71	30.00 ± 12.22	<0.001
Day 7	38.33 ± 13.67	53.33 ± 17.97	71.66 ± 13.37	<0.001
Day 9	44.44 ± 13.13	57.23 ± 15.42	80.55 ± 7.76	<0.001
Day 13	77.22 ± 13.16	75.55 ± 13.12	98.33 ± 3.01	<0.001
Day 14	96.11 ± 10.03	99.44 ± 1.92	100 ± 0.00	0.326

**Table 5.** Pairwise Comparison of Wound Contraction

Day	Comparison	Mean Difference (%)	p-value
Day 3	P1 – C1	23.33	0.001
	P1 – C2	23.88	<0.001
	C1 – C2	0.55	1.000
Day 7	P1 – C1	18.33	0.028
	P1 – C2	33.33	<0.001

Day 9	C1 – C2	15.00	0.327
	P1 – C1	23.33	0.006
	P1 – C2	36.11	<0.001
Day 13	C1 – C2	12.77	0.350
	P1 – C1	22.77	<0.001
	P1 – C2	21.11	<0.001
	C1 – C2	1.66	1.000



**Figure 1.** Illustrates the Progression of Incision Wound Healing in all Treatment Groups Over Time.

## DISCUSSION

Phytochemical analysis in this study confirmed that Pugima honey contains flavonoids, phenols, tannins, and saponins, which are known to contribute to wound healing processes. The findings demonstrated that Pugima honey significantly accelerated wound healing, as indicated by reduced wound length and increased wound contraction compared to the control groups.

The observed effects can be explained by the bioactive properties of these compounds. Flavonoids and phenolic compounds exhibit strong antioxidant activity, reducing oxidative stress during the inflammatory phase, when reactive oxygen species are released by neutrophils and macrophages.<sup>12</sup> This protective effect supports fibroblast and epithelial cell viability, thereby promoting tissue regeneration. In addition, phenolic compounds exert antibacterial activity against pathogens such as *Staphylococcus aureus* and *Escherichia coli*, which are known to delay wound healing.<sup>13</sup>

Furthermore, flavonoids modulate inflammatory responses by inhibiting mediators such as prostaglandins and proinflammatory cytokines (TNF- $\alpha$  and IL-6), thereby facilitating a faster transition from the inflammatory to the proliferative phase. Tannins contribute to hemostasis by enhancing platelet aggregation and reducing wound exudate.<sup>14,15</sup> These mechanisms collectively explain the faster wound closure observed in the treatment group.

During the proliferative phase, flavonoids, phenols, and saponins support fibroblast proliferation and collagen synthesis, which are essential for granulation tissue formation and epithelialization. Saponins also enhance wound contraction through the activation of myofibroblasts.<sup>16-19</sup> This is consistent with the significantly higher wound contraction rates observed in the Pugima honey group, indicating enhanced tissue remodeling.<sup>20</sup>

The present findings are consistent with previous studies demonstrating the effectiveness of honey, including Tualang and Manuka honey, in promoting wound healing through antimicrobial and anti-inflammatory mechanisms.<sup>21-23</sup> However, the effectiveness of Pugima honey may be influenced by its unique botanical origin from endemic Papuan flora, which potentially contributes to its distinct bioactive composition.<sup>24-25</sup>

Importantly, this study provides initial experimental evidence for the wound-healing efficacy of Pugima honey, a local natural resource that has not been previously evaluated in a controlled incision-wound model. This highlights its potential as a cost-effective and accessible therapeutic option.

Despite these promising results, several limitations should be acknowledged. Using a mouse model may not fully capture the complexity of human wound healing, particularly in chronic conditions such as diabetic ulcers or burns. Additionally, the absence of a negative control group limits the ability to fully compare baseline healing processes. Future studies are recommended to explore different wound models, optimize dosage, and evaluate clinical applicability in human subjects.

## CONCLUSIONS AND RECOMMENDATION

Pugima honey significantly enhances incision wound healing in a mouse model, as indicated by reduced wound length and increased wound contraction, particularly during the early to intermediate phases of healing. These findings suggest that Pugima honey has potential as a natural therapeutic agent for wound management. Further studies are needed to determine the optimal dosage and to evaluate its efficacy and safety in clinical settings.

## REFERENCES

- Wallace HA, Basehore BM, Zito PM. Wound healing phases. In: 2023.
- Masson-Meyers DS, Andrade TAM, Caetano GF, et al. Experimental models and methods for cutaneous wound healing assessment. *Int J Exp Pathol*. 2020;101(1-2):21-37. <http://dx.doi.org/10.1111/iep.12346>
- Mandal MD, Mandal S. Honey: its medicinal property and antibacterial activity. *Asian Pac J Trop Biomed*. 2011;1(2):154-160. [http://dx.doi.org/10.1016/S2221-1691\(11\)60016-6](http://dx.doi.org/10.1016/S2221-1691(11)60016-6)
- Morroni G, Alvarez-Suarez JM, Brenciani A, et al. Comparison of the antimicrobial activities of four honeys from three countries (New Zealand, Cuba, and Kenya). *Front Microbiol*. 2018;9(JUN):1-9. <http://dx.doi.org/10.3389/fmicb.2018.01378>
- Neo R, Gaonkar P, Huber L HK. Medical-grade honey has superior antibacterial properties against common bacterial isolates in wound cultures of dogs and cats in comparison to non-medical-grade honey types. *Am J Vet Res*. 2024;85(12):1-9. <http://dx.doi.org/10.2460/ajvr.24.07.0188>
- Haryanto H, Urai T, Mukai K, et al. Effectiveness of Indonesian honey on the acceleration of cutaneous wound healing: an experimental study in mice. *Wounds a Compend Clin Res Pract*. 2012;24(4):110-119.
- Nikpour M, Delavar MA, Khafri S, et al. The use of honey and curcumin for episiotomy pain relief and wound healing: A three-group double-blind randomized clinical trial. *Nurs Midwifery Stud*. 2019;8(2). [http://dx.doi.org/10.4103/nms.nms\\_74\\_17](http://dx.doi.org/10.4103/nms.nms_74_17)
- Aznan MI, Khan OH, Unar AO, et al. Effect of Tualang honey on the anastomotic wound healing in large bowel anastomosis in rats A randomized controlled trial. *BMC Complement Altern Med*. 2016;16:28. <http://dx.doi.org/10.1186/s12906-016-1003-6>
- Mukai K, Koike M, Nakamura S, et al. Evaluation of the effects of a combination of Japanese honey and hydrocolloid dressing on cutaneous wound healing in male mice. *Evid Based Complement Alternat Med*. 2015;2015:910605. <http://dx.doi.org/10.1155/2015/910605>
- Wulandini N, Hidajat D, Octora M. The efficacy of topical application of Sumbawa forest honey for wound healing: Study on incision wound of Balb/C male mice. 2021;64-67. <http://dx.doi.org/10.5220/0008150900640067>
- Haryani IGAD, Hervina, Pinatih MTS, Youngwoo L. Topical gel formulated with Ziziphus spina-Christi leaf extract decreases lymphocyte infiltration in gingival incision wounds. *Interdental J Kedokt Gigi*. 2025;21(3):394-400. <http://dx.doi.org/10.46862/interdental.v21i3.12200>
- Banjarnahor SDS, Artanti N. Antioxidant properties of flavonoids. *Med J Indones*. 2014;23(4):239-244. <http://dx.doi.org/10.13181/mji.v23i4.1015>
- Rudrapal M, Khairnar SJ, Khan J, et al. Dietary polyphenols and their role in oxidative stress-induced human diseases: Insights into protective effects, antioxidant potentials and mechanism(s) of action. *Front Pharmacol*. 2022;13:806470. <http://dx.doi.org/10.3389/fphar.2022.806470>
- Kassym L, Kussainova A, Semenova Y, McLoone P. Antimicrobial effect of honey phenolic compounds against E. coli—An in vitro study. *Pharmaceuticals*. 2024;17(5). <http://dx.doi.org/10.3390/ph17050560>
- Zainol MI, Mohd Yusoff K, Mohd Yusof MY. Antibacterial activity of selected Malaysian honey. *BMC Complement Altern Med*. 2013;13(1):129. <http://dx.doi.org/10.1186/1472-6882-13-129>
- Masad RJ, Haneefa SM, Mohamed YA, et al. The immunomodulatory effects of honey and associated flavonoids in cancer. *Nutrients*. 2021;13(4). <http://dx.doi.org/10.3390/nu13041269>

17. Silva B, Biluca FC, Gonzaga LV, et al. In vitro anti-inflammatory properties of honey flavonoids: A review. *Food Res Int.* 2021;141:110086. <http://dx.doi.org/10.1016/j.foodres.2020.110086>
18. Yaghoobi R, Kazerouni A, Kazerouni O. Evidence for clinical use of honey in wound healing as an antibacterial, anti-inflammatory, antioxidant and anti-viral agent: A review. *Jundishapur J Nat Pharm Prod.* 2013;8(3):100-104. <http://dx.doi.org/10.17795/ijnpp-9487>
19. Lia Novita Sari, Debie Dahlia DAK. Penggunaan madu terhadap perbaikan kondisi klinis dalam proses penyembuhan luka pada pasien ulkus diabetikum. *J Telenursing.* 2024;6(2):2897-2905. <http://dx.doi.org/10.31539/joting.v6i2.4142>
20. Sieniawska E. Activities of tannins—from in vitro studies to clinical trials. *Nat Prod Commun.* 2015;10(11):1877-1884. <http://dx.doi.org/10.1177/1934578X1501001118>
21. Mathew-Steiner SS, Roy S, Sen CK. Collagen in wound healing. *Bioengineering.* 2021;8(5). <http://dx.doi.org/10.3390/bioengineering8050063>
22. Thakur R, Jain N, Pathak R, Sandhu SS. Practices in wound healing studies of plants. *Evidence-Based Complement Altern Med.* 2011;2011(1):438056. <http://dx.doi.org/10.1155/2011/438056>
23. Ahmed S, Othman NH. Review of the medicinal effects of tualang honey and a comparison with manuka honey. *Malays J Med Sci.* 2013;20(3):6-13.
24. Abdallah WE, Shams KA, El-Shamy AM. Phytochemical analysis and evaluation of its antioxidant, antimicrobial, and cytotoxic activities for different extracts of *Casuarina equisetifolia*. *BMC Complement Med Ther.* 2024;24(1):128. <http://dx.doi.org/10.1186/s12906-024-04422-4>
25. Syamsul TD, Natzir R, As S, Hadju V, Hatta M. The chemical composition of Trigona honey in Bone, South Sulawesi. *Indian J Public Heal Res Dev.* 2020;11(9):258-263. <http://dx.doi.org/10.37506/ijphrd.v11i9.11018>